

CASE REPORT

One-year Follow-up of Socket Shield on a Molar Site

Haseeb Al Dary¹, Lina Droubi²

ABSTRACT

This case report aims to illustrate the possible advantages of applying the socket-shield technique to preserve peri-implant buccal tissues in molar site and its stability after 1 year. An upper first molar was selected for extraction and implant replacement, applying the socket-shield concept, the palatal root and the palatal section of the buccal roots were removed leaving the buccal section of the buccal roots as a shield; then, an implant was inserted in the appropriate position simultaneously. After 5 months, the implant was loaded and followed up for 1 year. It was found that the socket shield was stable and successfully preserved the hard and soft tissue around the implant; we came to a conclusion that socket-shield technique may provide a way to offset alveolar ridge post-extraction changes and thereby enhancing the overall esthetic and functional results.

Keywords: Immediate implant, Molar, Socket preservation, Socket shield.

How to cite this article: Dary H, Droubi L. One-year Follow-up of Socket Shield on a Molar Site. *Int J Med Oral Res* 2018;3(2):25-31.

Source of support: Nil

Conflicts of interest: None

INTRODUCTION

It is scientifically established that after tooth extraction, alveolar bone undergoes resorption and remodeling process, ending up losing a significant volume of the hard tissue and accordingly soft tissue changes follows, in a recent systematic review by Tan *et al.*^[1] It was found that 6 months after extraction, horizontal bone loss ranged between (29 and 63%) and vertical bone loss between (11 and 22%), and for decades, alveolar bone preservation was a major concern for clinician worldwide, socket preservation, guided bone regeneration, bone grafts, and bone regeneration were among the approaches attempted to prevent or counteract this physiological bone resorption process, but regardless of their ability to improve or slow down the bone loss, no

particular technique was capable of completely preserving the alveolar bone.

In 2010, the concept of socket shield and immediate implant insertion in the anterior zone was introduced by Hurzeler *et al.*,^[2] the technique implied sectioning a remaining root longitudinally in a mesiodistal direction and extracting the palatal part leaving the buccal part in place to act as the socket shield, then inserting the implant palatal to it, this technique claimed that leaving the buccal root section preserved the periodontal ligament (PDL) and the bundle bone along with it and so preserving the bone in that area from resorption, providing a stable hard and soft tissue structure.

As the posterior area is not esthetically as demanding as the anterior area, socket-shield technique was not applied posteriorly often, most data available studied the socket shield in the anterior zone, yet, the importance of tissue preservation in posterior zone should not be underestimated, as good hard and soft tissue volume is considered of paramount importance for the long-term success and maintenance of dental implants.

In this case report, we applied the socket-shield concept as presented by Hurzeler *et al.* in the molar region.

CASE PRESENTATION

A 48-year-old healthy female patient presented to the clinic complaining from a badly destructed upper right first molar and asking for a restoration. On investigation, medical history was insignificant, no known allergies and the patient was non-smoker. Clinical examination revealed an asymptomatic upper first molar, in which the decay destroyed the entire crown, no ferrule effect was left to be used to support a post and core or to have it restored and the tooth was judged to be unrestorable [Figures 1-3]. Radiographic examination revealed a good endodontic treatment with no pathological findings. After discussing the treatment options with the patient, she accepted and consented on doing partial extraction "socket-shield technique" with immediate implant placement.

MATERIALS AND METHODS

Infiltration anesthesia on buccal and palatal side was given using lidocaine hydrochloride 2% (Septodont).

1. All occlusal caries was removed with tungsten carbide bur [Figure 4]

¹General Practitioner, ²Periodontist

¹Doctor of Dental Surgery (DDS), General Practitioner, Jordan

²Periodontist, Jordan

Corresponding Author: Haseeb Al Dary, Doctor of Dental Surgery (DDS), General Practitioner, Jordan. e-mail: haseeb@yahoo.com

2. A mesiodistal cut was made to separate the palatal root using a coarse conical bur [Figure 5]
3. A straight elevator was placed between the palatal and buccal roots to insure complete separation; then, the palatal root was luxated very gently to perform an atraumatic extraction of the palatal root

4. The gutta-percha of the remaining buccal root canals was partially removed

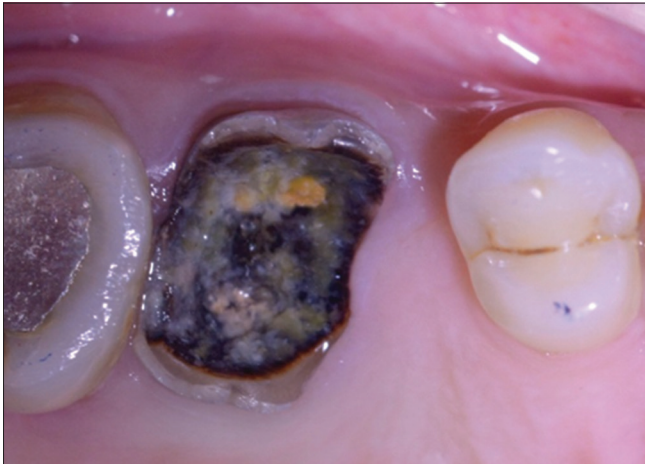

Figure 1: Pre-operative occlusal view showing the non-restorable tooth structure

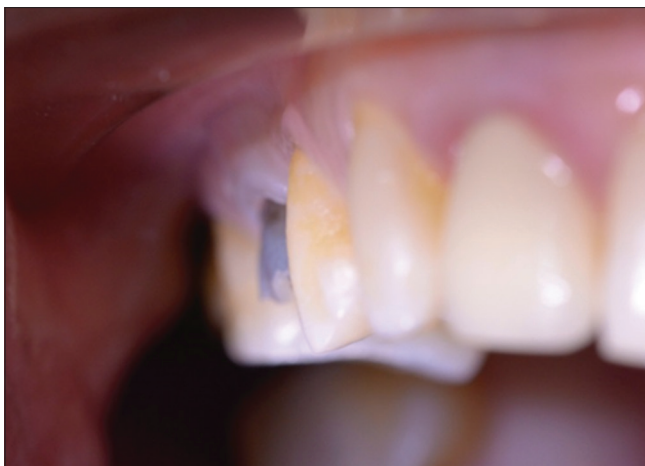

Figure 2: A frontal view showing the emergence profile of the non-restorable molar comparing to the adjacent teeth

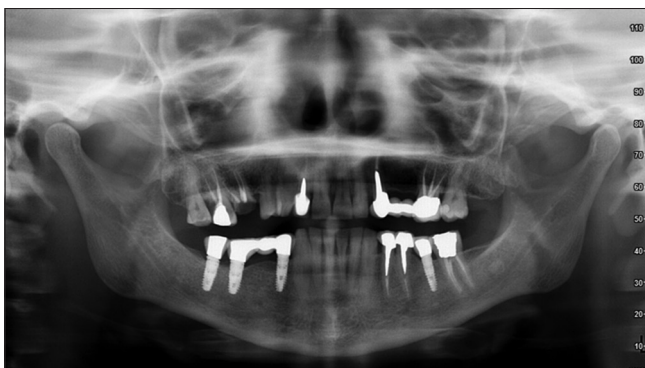


Figure 3: Pre-operative panoramic radiograph showing no pathologic findings around the apices of the well-treated root canals of the non-restorable upper right first molar

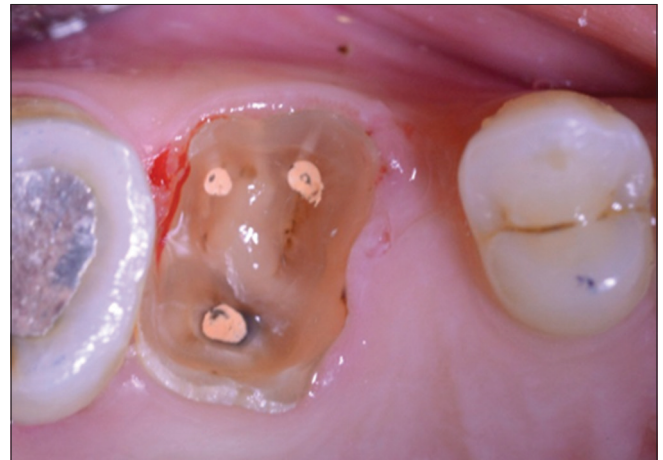


Figure 4: Occlusal view showing the cleaning the decayed tooth and removal of caries to a subgingival level before starting the extraction

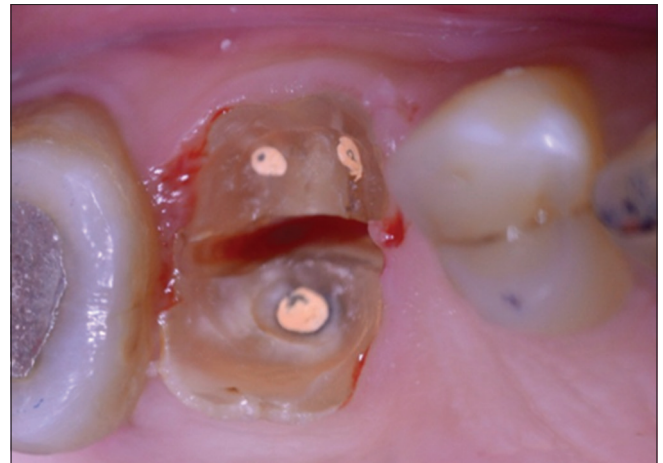

Figure 5: Occlusal view showing the separation of the palatal root from the two buccal roots

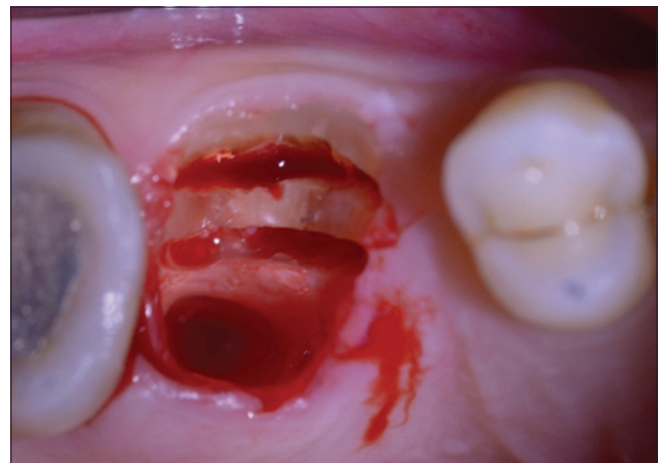


Figure 6: Occlusal view showing the removal of the palatal root and the dissection of the buccal roots mesiodistally along an axis connecting between the root canal orifices, creating two halves of the roots buccal to be left intact "socket shield," palatal to be extracted

A mesiodistal dissection along the long axis of the two roots was started between the two orifices [Figure 6], then the dissection was extended to the mesial wall of the mesiobuccal root from one end and the distal wall of the distobuccal root from the other end using a coarse conical diamond bur to its full working length which is almost 7 mm, tactile sensation helps to realize the difference between the comparatively harder tooth structure and bone structure while drilling, which helps to decide when to stop the cutting in the mesiodistal direction, the palatal fragment was further dissected to facilitate atraumatic removal [Figure 7]. The straight elevator was used once again and placed on the cut line with the convex surface facing the buccal fragments and the concaved surface facing the palatal fragment, a gentle twisting movement directing the forces toward the palatal part, saving the buccal part from being traumatized was performed to create a crack splitting the two parts from each other's, the palatal fragments were then gently removed with a tweezers

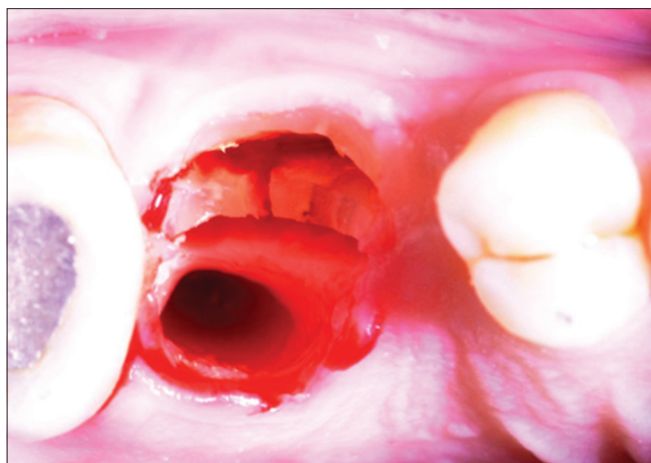


Figure 7: Occlusal view showing the dissection of the palatal fragments of the buccal roots to facilitate extraction to prevent from traumatizing the socket shield

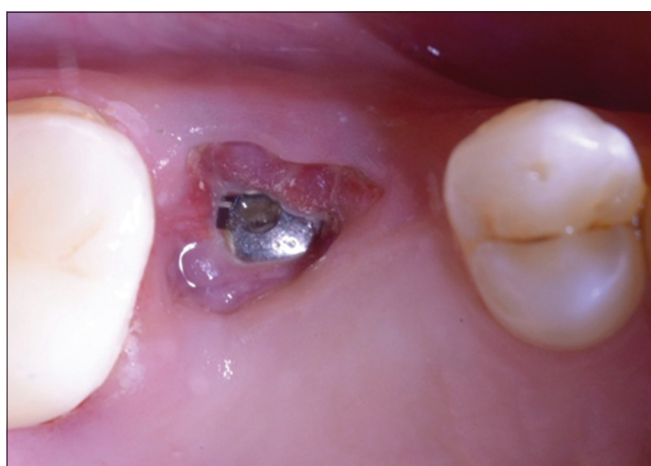

Figure 8: A 5-week follow-up, soft tissue is covering the root fragments

5. Periapical radiography was used to help visualize how much of the root structure and gutta-percha filling were left inside the socket, thus aided their removal using a tapered diamond bur and preparing the palatal side of the remaining mesio- and disto-buccal fragments, in a way ensuring the removal of all remnants of the gutta-percha endodontic filling, Leaving a shell of around 0.5–1 mm thickness of the two roots "socket-shield" intact and attached to bone
6. A diamond round bur was used to reduce the occlusal height of the remaining part of the roots to the level of gingival sulcus depth after measuring the depth with periodontal probe, which was about 0.5 mm yet leaving it coronal to the bone crest. However, this height was further reduced in subsequent sessions due to exposure [Figures 8-10].
7. Serial drilling was performed to prepare osteotomy site for the implant "Tiologic 4.8 × 11 mm"

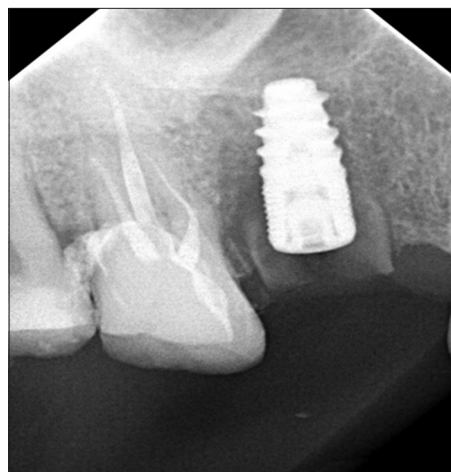


Figure 9: Periapical radiograph after the removal of the exposed parts of the fragments after 5 weeks

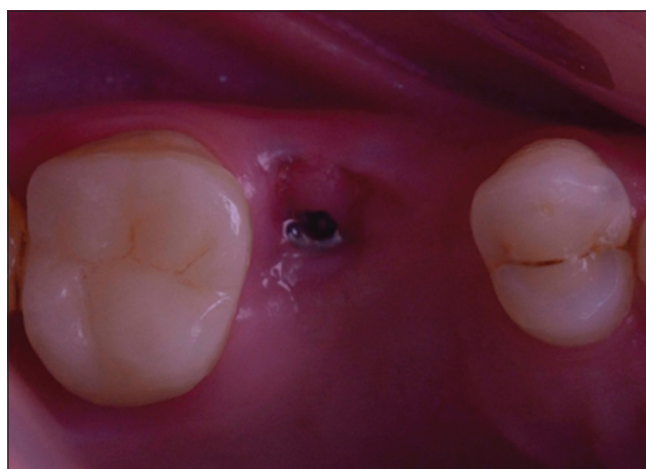


Figure 10: An 11-week follow-up, a little exposure of the root fragments can be seen

in the middle of the mesiodistal distance between the sockets of the two buccal roots and palatal to it [Figure 11], the implant was placed in a

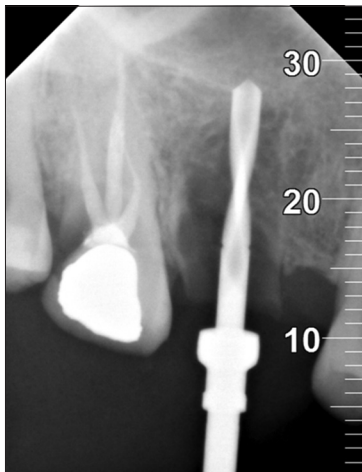


Figure 11: Periapical radiograph of pilot drill preparing for the implant bed in the middle of the mesiodistal dimension of the tooth after the socket shield was prepared

three-dimensional design in such a way that its platform is 3 mm apical to the occlusal extent of the socket shield [Figures 12 and 13]. Maximum torque obtained was 25 Newton, a cover screw was placed and the implant was left to heal unloaded for 5 months [Figures 14 and 15], afterward, a pickup impression and final prosthesis “zirconia crown”

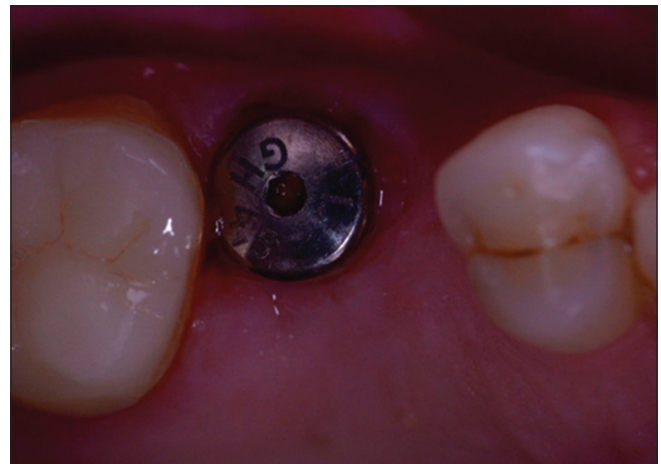


Figure 14: Occlusal view of the gingival former after 12 weeks

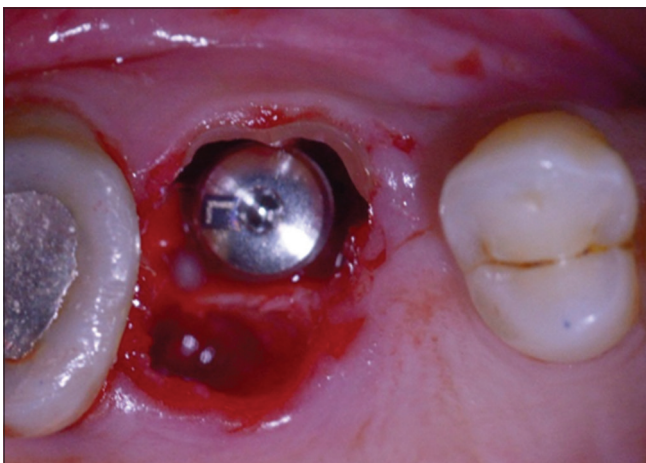


Figure 12: Implant installed in the middle distance of the two buccal roots, touching the very thin buccal shield, and not taking in consideration the 2–3 mm gap between the implant and the buccal bone as the recommendation of literature suggest

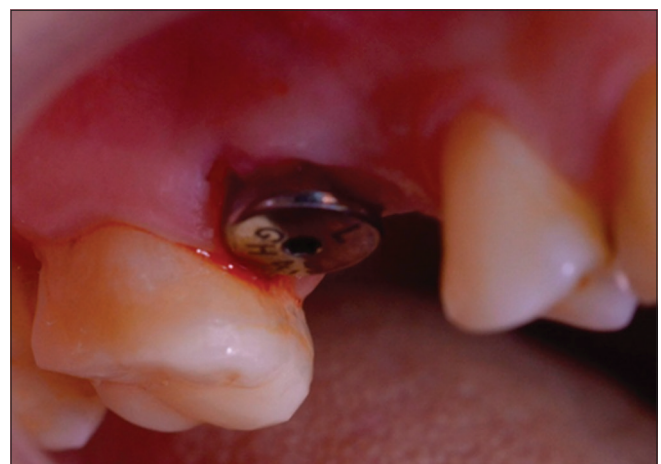

Figure 15: Lateral view of the gingival former

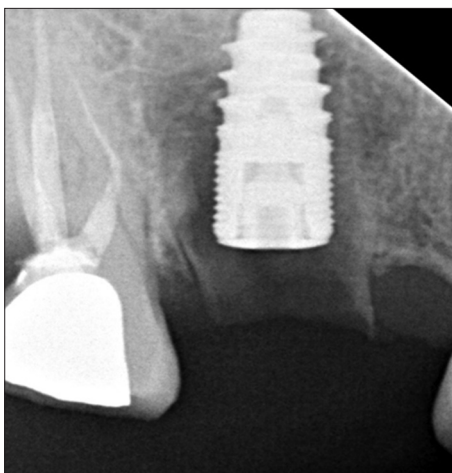


Figure 13: Periapical radiograph showing the implant in place and the socket shield raising above the crest of the ridge

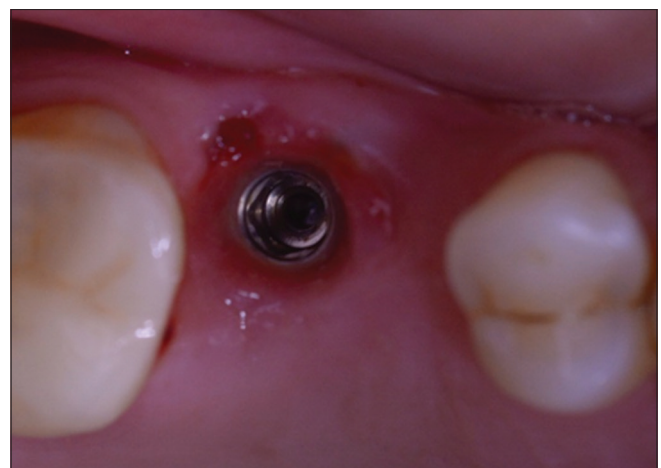


Figure 16: Removal of gingival former and the exposure of a little part of the fragment once again

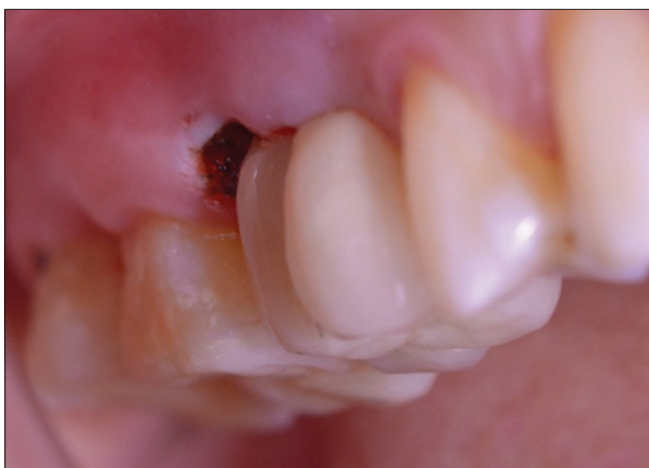

Figure 17: Crown delivery and removing the exposed part of the fragment once again

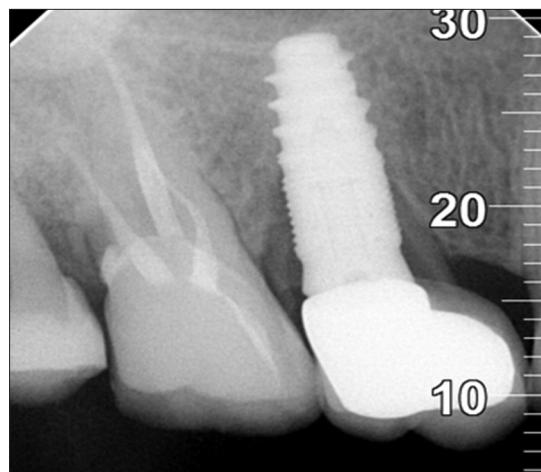


Figure 20: Periapical radiograph with 12-month follow-up

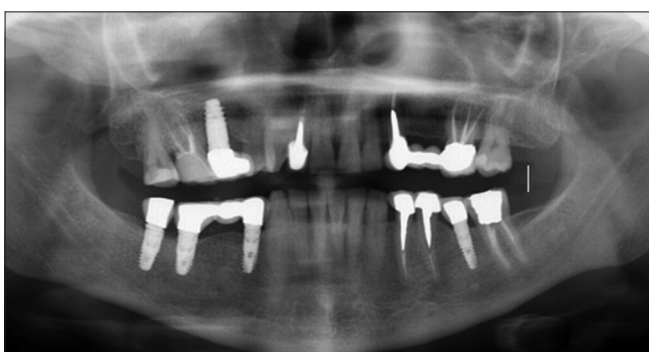

Figure 18: Panoramic radiograph with 6-month follow-up

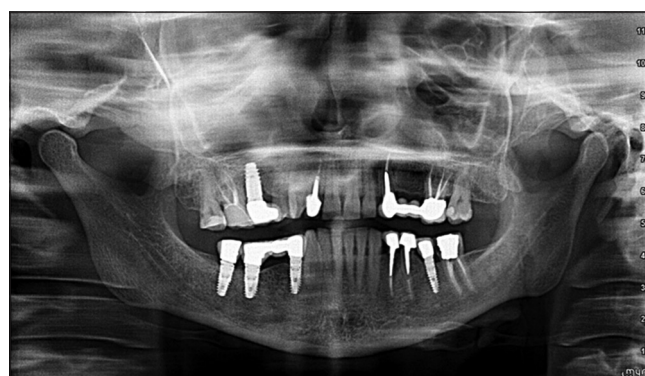


Figure 21: Panoramic radiograph with 12-month follow-up

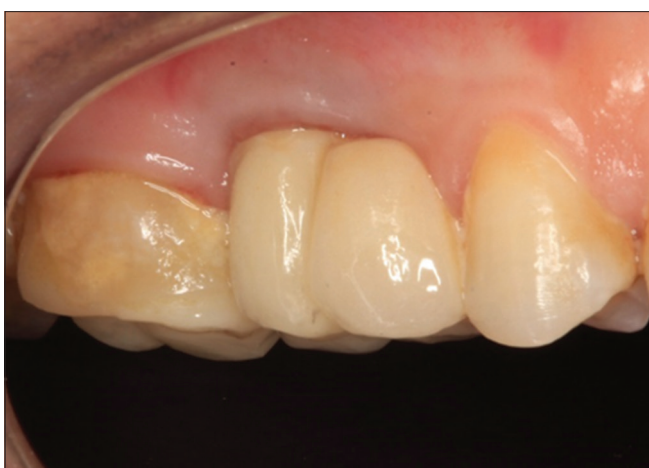

Figure 19: Lateral view of the crown with 12-month follow-up

were fabricated and placed on the implant abutment [Figures 16 and 17].

8. The patient was recalled for follow-up and examination at 6 and 12 months post-treatment [Figures 18-21].

RESULTS

The implant has osseointegrated and the buccal shield remained submerged without complications, buccal

peri-implant soft tissue seems to have stayed stable at 1-year follow-up.

DISCUSSION

After teeth removal, the alveolar ridge undergoes a series of physiological events, resulting in substantial reduction in its volume;^[3] similarly, studies on changes after single tooth extraction showed that the ridge at the site is markedly reduced^[4] both in buccolingual/palatal and apicocoronal direction, the authors concluded not only that the loss was substantial but also that the reduction at the buccal aspect was twice as large as the palatal/lingual aspect. These conclusions were supported by findings presented by Schropp *et al.*, 2003,^[5] who calculated a loss of 50% of the original ridge width at 12-month post-extraction. Furthermore, Sanz *et al.*, 2010,^[6] in a clinical study came to a conclusion that the resorption of the buccal plate varied according to its original dimensions, accordingly buccal plates that were <1 mm thick lost substantially more dimensions than plates that were more than 1 mm thick.

Ever since Branemark discovery of osseointegration of titanium implants, implants have increasingly become the treatment of choice for tooth loss replacement, and

thousands of implants have been inserted worldwide in the past decades, although successful osseointegration was predictable and highly expected, the success of implants as a treatment modality has been questioned as more demands in esthetics and even functional outcomes have evolved, redefining implant success to include acceptable results on those terms too. Many factors played a role in the outcome of implant treatment such as amount of bone for proper positioning, contour of soft tissues, gingival margin, and amount of keratinized tissue to name a few.

Many techniques have evolved in attempts to either preserve or augment deficient alveolar ridge in order to receive implants in a proper position, of these ridge preservation technique showed favorable results yet the results depended on many variables including the socket morphology, type of wound closure, type of grafting materials, use of barrier membranes and use of growth factors,^[7] another approach was immediate implant insertion at the time of extraction which was thought to counteract the above mentioned post extraction bone resorption, yet studies have shown that immediate implantation could not preserve the bone, and physiological bone remodeling after tooth extraction is inevitable, furthermore the effect of regenerative therapy combined with immediate implant insertion after tooth extraction was investigated by De Angelisi *et al.* 2011^[8] and the authors reported a more favorable outcomes however they disclosed that single post extraction implants might be at higher risks of implants complications. Early implant placement protocol was studied also, as a way to overcome some of the shortcoming of immediate implant placement with bone graft, namely the shortage in soft tissue and tension-free primary coverage and the complications that compromised the regeneration therapy such as membrane exposure, studies revealed results favoring the early implant placement protocol over the immediate implant placement^[9] and better esthetic parameters of early implant placement, yet these differences were lost at 5-year follow-up.^[10,11]

On the other hand and as implants are being investigated intensely by clinicians all over the world, more parameters are becoming recognized to play a role in the final outcome, one that seems to have a significant importance is the gingival biotype. In general, gingival soft tissue has been classified into two major types: Thick flat and thin scalloped, studies have shown that thin biotype is associated with thin buccal plate and thick biotype with thick buccal plate, many authors suggested that having a thick buccal plate is associated with a better prognosis for peri-implant tissues stability. Sammartino *et al.*^[12] found that the thickness of the

buccal plate has a prognostic value on implant esthetics; furthermore, Buser *et al.*^[13] and Bashutski and Wang^[14] proposed a minimum of 2.0 mm buccal bone thickness for an acceptable implant aesthetics. Some studies also observed the correlation between tissue thickness and bone crest stability around implants and others suggested that a thick soft tissue was associated with more stable bone margin.

In general, many studies have reached a conclusion that cases with thin gingival biotype are associated with less stable bone levels and accordingly less predictable overall esthetic results of implants on the long term.

According to the above, it's becoming more obvious that although many approaches were able to improve the clinical parameters to a good degree, none of them were able to totally preserve pre-extraction hard and soft tissue dimensions and morphology. In 2010, Hurzeler *et al.* described the socket shield technique, based on the fact that bundle bone depends mainly on PDL for its nourishment and that its resorption after tooth extraction is due to loss of PDL along with the tooth, thus loss of the bundle bone main blood supply. Hurzeler *et al.* suggested that by leaving the buccal root section with its attached PDL with immediate implant inserted palatal to it, bundle bone preservation can be expected preserving the hard and soft tissue buccally and so achieving a stable peri-implant tissue for optimum esthetic outcome in the anterior zone. Socket-shield technique in the anterior zone has been studied ever since by many clinicians with promising results, yet so far very few attempted applying this concept to the posterior area. Although the posterior zone carries much less esthetic demands, the importance of having a stable soft and hard tissue around implants on the long-term success and maintenance cannot be underestimated, problems such as shallow or absent vestibule, no enough keratinized tissue around the implant could be avoided or minimized by applying the socket-shield concept to the molar sites.

CONCLUSIONS

This case report demonstrates that the socket-shield technique may aid to offset the alveolar bone and soft tissue changes usually observed after tooth extraction of molar teeth, particularly preserving the height and dimensions of the buccal plate around the implant and consequently might aid in preserving keratinized tissue and the vestibular depth in the area, all of which contributed to achieving a stable healthy environment and improved oral hygiene and maintenance of the implant along with better more predictable esthetics. That said, this approach is considered technique sensitive and might be associated with many complications

and requires outstanding skills, so it is recommended to be left to the clinician judgment and preference along with precise evaluation of each particular case individually to decide whether applying socket-shield concept is appropriate or not.

REFERENCES

1. Tan WL, Wong TL, Wong MC, Lang NP. A systematic review of post extractional alveolar hard and soft tissue dimensional changes in humans. *Clin Oral Implant Res* 2012;23 Suppl 5:1-21.
2. Hürzeler MB, Zuhr O, Schupbach P, Rebele SF, Emmanouilidis N, Fickl S. The socket-shield technique: A proof-of-principle report. *J Clin Periodontol* 2010;37:855-62.
3. Bergman B, Carlson GE. Clinical long term study of complete denture wearers. *J Prosthet Dent* 1985;53:56-61.
4. Pietrokovski J, Massler M. Alveolar ridge resorption following tooth extraction. *J Prosthet Dent* 1967;17:21-7.
5. Schropp L, Wenzel A, Kostopolous L, Karring T. Bone healing and soft tissue contour changes following single tooth extraction: A clinical and radiographic 12-month prospective study. *Int J Period Restor Dent* 2003;23:313-23.
6. Sanz M, Cecchinato D, Ferrus J, Pjetursson EB, Lang NP, Lindhe J, *et al.* A prospective randomized-controlled clinical trial to evaluate bone preservation using implants with different geometry placed into extraction sockets in the maxilla. *Clin Oral Implants Res* 2010;21:13-21.
7. Bassir SH, Alhareky M, Wangsrimongkol B, Jia Y, Karimbux N. Systematic review and meta-analysis of hard tissue outcomes of alveolar ridge preservation. *Int J Oral Maxillofac Implants* 2018;33:979-94.
8. De Angelis N, Felice P, Pellegrino G, Camurati A, Gambino P, Esposito M. Guided bone regeneration with and without a bone substitute at single post-extractive implants: 1-year post-loading results from a pragmatic multicentre randomised controlled trial. *Eur J Oral Implantol* 2011;4:3-25.
9. Sanz I, Garcia-Gargallo M, Herrera D, Martin C, Figuero E, Sanz M, *et al.* surgical protocols for early implant placement in post-extraction sockets: A systematic review. *Clin Oral Implants Res* 2012;23 Suppl 5:67-79.
10. Schropp L, Isidor F, Kostopoulos L, Wenzel A. Patient experience of, and satisfaction with, delayed-immediate vs delayed single-tooth implant placement. *Clin Oral Implant Res* 2004;15:498-503.
11. Schropp L, Isidor F. Timing of implant placement relative to tooth extraction. *J Oral Rehabil* 2008;35 Suppl 1:33-43.
12. Sammartino G, Marenzi G, di Lauro AE, Paolantoni G. Aesthetics in oral implantology: Biological, clinical, surgical, and prosthetic aspects. *Implant Dent* 2007;16:54-65.
13. Buser D, Martin W, Belser UC. Optimizing esthetics for implant restorations in the anterior maxilla: Anatomic and surgical considerations. *Int J Oral Maxillofac Implants* 2004;19:43-61.
14. Bashutski JD, Wang HL. Common implant esthetic complications. *Implant Dent* 2007;16:340-8.